

A Magnetic Resonance Imaging Study of Cerebellar Volume in Tuberous Sclerosis Complex

Neil I. Weisenfeld, Jurriaan M. Peters, Peter T. Tsai, Sanjay P. Prabhu, Kira A. Dies, Mustafa Sahin, and Simon K. Warfield
Pediatric Neurology, 2013-02-01, Volume 48, Issue 2, Pages 105-110
Copyright © © 2013 Elsevier Inc.

Abstract

The cerebellum plays an important role in motor learning and cognition, and structural cerebellar abnormalities have been associated with cognitive impairment. In tuberous sclerosis complex, neurologic outcome is highly variable, and no consistent imaging or pathologic determinant of cognition has been firmly established. The cerebellum calls for specific attention because mouse models of tuberous sclerosis complex have demonstrated a loss of cerebellar Purkinje cells, and cases of human histologic data have demonstrated a similar loss in patients. We hypothesized that there might be a common cerebellar finding in tuberous sclerosis complex that could be measured as morphometric changes with magnetic resonance imaging. Using a robust, automated image analysis procedure, we studied 36 patients with tuberous sclerosis complex and age-matched control subjects and observed significant volume loss among patients in the cerebellar cortices and vermis. Furthermore, this effect was strongest in a subgroup of 19 patients with a known, pathogenic mutation of the tuberous sclerosis 2 gene and impacted all cerebellar structures. We conclude that patients with tuberous sclerosis complex exhibit volume loss in the cerebellum, and this loss is larger and more widespread in patients with a tuberous sclerosis 2 mutation.

Introduction

Tuberous sclerosis complex is a rare, genetic, neurocutaneous disorder affecting 1 in 6000 live births, with approximately 40,000 cases in the United States and more than one million worldwide [1][2]. Although some children with the disease remain cognitively intact, more than 40% have intelligence quotients below 70 [3], and many are eventually diagnosed with an autism spectrum disorder [4][5]. The vast majority of children with tuberous sclerosis complex will also suffer from epilepsy during their lifetime [6].

Tuberous sclerosis complex is an autosomal dominant disorder caused by germ line mutations in either of two genes: *TSC1* and *TSC2*. Pathogenic mutations in either gene lead to dysregulation of mammalian target of rapamycin signaling and, in turn, excessive translation of proteins associated with cell growth and with the physical manifestations of the disease. Within the brain, these physical signs include tubers, subependymal nodules, and subependymal giant cell astrocytomas. The relationship between these gross morphologic brain abnormalities and cognitive phenotype remains difficult to establish.

Although previous morphologic studies with magnetic resonance imaging (MRI) have focused largely on cortical tubers, subependymal giant cell astrocytomas, and subependymal nodules, recent evidence indicates that there may be other structural abnormalities more strongly related to cognitive phenotype [7]. Recent findings of Purkinje cell loss in a mouse model of tuberous sclerosis complex [8] and in several cases of human histology [8][9], combined with evidence that the cerebellum plays a key role in learning and cognition [10][11], motivated us to test whether there are morphologic differences in the cerebellum in tuberous sclerosis complex that are observable in vivo by use of magnetic resonance imaging (MRI).

Methods

Subjects

A cohort of 36 patients with tuberous sclerosis complex (ages 1-27 years) was recruited from the Multi-Disciplinary Tuberous Sclerosis Program at Children's Hospital Boston, and 36 age-matched control subjects (ages 1-25 years) were recruited from the community. Control subjects underwent imaging as part of their routine care or as part of this research study. Each MRI was reviewed by a pediatric neuroradiologist (S.P.P.), and all control subjects had normal MRI results and normal neurologic examination results. Subject demographics are presented in Table 1. Patients fulfilled the clinical criteria for definite tuberous sclerosis complex, as defined by the Tuberous Sclerosis Complex Consensus Conference [12], and underwent genetic testing that included *TSC1* and *TSC2* gene sequencing and microdeletion analysis. Genetic testing was performed by two clinical laboratories: Athena Diagnostics (Worcester, MA) and Boston University School of Medicine Center for Human Genetics (Boston, MA). Twenty-six patients had their diagnoses confirmed by genetic testing (19 TSC2, 7 TSC1). In other patients, either testing was not performed or failed to find a known, pathogenic mutation.

Table 1

Study demographics

Characteristic	TSC	Control subjects
Sample (*TSC1*/ *TSC2*/unknown)	36 (7/19/6)	36
Sex (M:F)	23:13	17:19
Age (Mean ± SD)	9.7 ± 6.6	9.7 ± 6.5 *
Phenytoin exposure (*TSC1*/ *TSC2*/unknown)	7 (1/4/1)	
ACTH exposure (*TSC1*/ *TSC2*/unknown)	3 (0/2/1)	
Cerebellar tubers (*TSC1*/ *TSC2*/unknown)	3 (0/1/2)	

*Paired *t*-test t = 0.41; *P* = 0.68.

Standard protocol approvals, registrations, and patient consents

All recruitment and imaging was performed in accordance with an institutional review board–approved protocol. Written, informed consent was obtained for each participant.

Data acquisition

To enable morphometric examination of the cerebellum in vivo, MRI was used. Imaging was performed on a 3-T Siemens Tim Trio (Siemens, Erlangen, Germany) magnetic resonance imager with a 32-channel head coil. Computational morphometry studies of the cerebellum used images of each patient from two pulse sequences: (1) T_1-weighted images acquired with MPRAGE (TE 2.27ms/TI 800ms/TR 1410ms), FOV 240, matrix 256, slice thickness 1.0 mm, spacing 0 and (2) T_2-weighted images acquired by use of Turbo Spin Echo (TE 85ms/TR 16000ms), field-of-view 200, matrix 192, echo train length 11, slice thickness 1.2 mm, spacing 0. Images for this study were acquired without contrast media.

Data analysis

The primary measure in this study was regional tissue volume. Although automatic delineation of the cerebellum can be challenging because of unexpected size and shape variation in disease, it is necessary to avoid the bias and variability associated with hand-drawn measurements and to enable observer-independent analysis of large patient data sets. To reliably label the cerebellum in these patients, we used a two-step procedure in which image voxels were first labeled on the basis of image appearance as gray matter, white matter, or non-brain tissue. Voxels labeled as gray or white matter were then further subdivided, on the basis of anatomic position, into left cerebellar hemisphere, right cerebellar hemisphere, vermis, and noncerebellar tissue. This two-step procedure, with both appearance and location features used, allowed us to avoid errors likely if location cues alone were used. Details of this procedure are as follows.

The initial segmentation of gray matter and white matter by use of image appearance features was performed with a previously validated automatic segmentation procedure [13][14] on the basis of the joint distribution of image intensities in each subject's T_1- and T_2-weighted images. This technique uses highly flexible, nonlinear registration (Advanced Normalization Tools) [15] to warp example segmentations to the target image under study. These example segmentations are then used to train a supervised classifier to generate the probability of each tissue class at each voxel. Unlike label fusion approaches, our algorithm learns the pattern of intensities specific to a particular structure in a particular individual's image and is therefore robust to changes in anatomy.

The separation of the cerebellum from the rest of the brain on the basis of location cues, as well as the separation of the hemispheres and vermis from one another, was performed with a label fusion procedure [16]. Each of 15 labeled example images was warped to the target subject, and a consensus was generated for the left and right hemispheres and vermis with the MAP STAPLE algorithm [17][18]. Fig 1 shows three orthogonal views of a single subject with a color-coded overlay of the cerebellar segmentation showing left and right cerebellar cortices, central cerebellar white matter, and vermis.

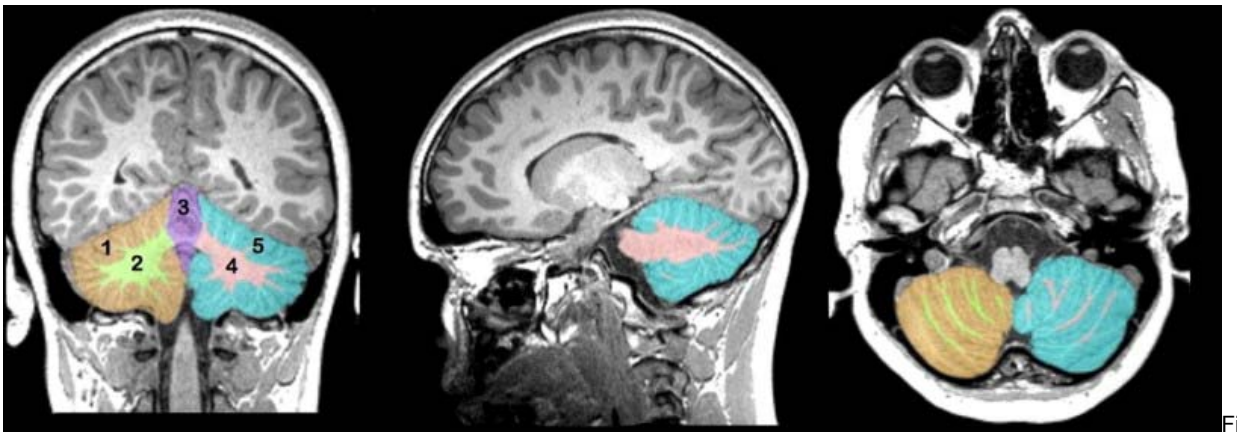

Figure 1

The cerebellum was segmented automatically without examiner interaction. Displayed from left to right are coronal, sagittal, and axial views of a single subject's T_1-weighted magnetic resonance image (see text) with the five identified cerebellar regions overlaid in color. Shown are the (1,5) cerebellar cortex, (2,4) central cerebellar white matter, and the vermis (3).

Results

Tissue volumes were generated for the cerebellar vermis, and for gray matter and white matter in each of the left and right cerebellar hemispheres, for a total of five measures per subject. Comparisons were performed with linear regression to explain regional tissue volume on the basis of group membership (e.g., tuberous sclerosis complex vs. control). Given the wide range of ages studied (1-27), it was necessary to correct for differences in overall brain size caused by development. Total intracranial volume (brain parenchyma and cerebrospinal fluid) is suitable for this purpose [19] and was used as a confound to correct for global size. Because long-term exposure to phenytoin has been associated with cerebellar atrophy [20], it was necessary to test for an effect related to the drug. Given the limited degrees of freedom afforded by the sample size, separate regression models were fit for each structure, and false discovery rate control [21] was used to account for multiple comparisons. Each regression model was of the form:

volume=β0+β1TSC+β2TIV+β3PHT

where *volume* is the measured tissue volume (response), *TSC* is a group indicator for tuberous sclerosis complex, *TIV* is the total intracranial volume to control for head size, and *PHT* is an indicator for *any* exposure to phenytoin during the patient's lifetime.

Regression analyses are shown in Table 2. The significance of each coefficient was assessed with a two-tailed t-test with the null hypothesis that the coefficient is zero and therefore does not contribute to the model. Group membership (*TSC*) contributed significantly to the volume of the cerebellar cortices (left and right) and vermis, with patients with tuberous sclerosis complex exhibiting significant reductions in volume in these structures. There was no significant effect for phenytoin exposure.

Table 2

Patients with tuberous sclerosis complex have widespread cerebellar volume loss

		TSC vs. control subjects (n = 36/36)			TSC2 vs. control subjects (n = 19/19)		
Structure	**Variable**	**Coefficient**	**t-value (*df* = 68)**	***P* value**	**Coefficient**	**t-value (*df* = 34)**	***P* value**
Cortex L	TSC	−3.65e+3	−3.39	0.00118 *	−6.22e+3	−4.40	0.0001 *
PHT	−8.63e+2	−0.475	0.636	1.72e+3	0.747	0.460	
Cortex R	TSC	−3.82e+3	−3.77	0.000343 *	−6.18e+3	−5.11	0.0000123 *
PHT	−4.22e+2	−0.248	0.805	1.162e+2	0.59	0.559	
White matter L	TSC	−4.34e+2	−1.40	0.166	−1.03e+3	−2.40	0.0219 *
PHT	−5.62e+2	−1.08	0.286	−4.12e+2	−0.588	0.5603	
White matter R	TSC	−3.98e+2	−1.28	0.206	−9.77e+2	−2.18	0.0366 *
PHT	−7.99e+2	−1.523	0.132	−9.02e+2	−1.23	0.227	
Vermis	TSC	−6.57e+2	−2.90	0.00501 *	−8.83e+2	−2.89	0.00675 *

PHT	4.51e+2	1.18	0.242	1.80e+3	2.171	0.03704

Significant values after false discovery rate control with (q = 0.05, alpha = 0.05) are marked with an asterisk.

The data were further subdivided on the basis of genetic analysis. Nineteen patients had known, pathogenic mutations of *TSC2*, whereas only seven patients had known mutations of *TSC1*. Patients with mutations of unknown significance were not considered. Because of the small sample size of patients with *TSC1* mutations, only patients with *TSC2* mutations were compared statistically with control subjects in this subgroup analysis. The *TSC2* regression analysis is shown in Table 2 (right column) and demonstrates significant volume loss for patients with *TSC2* mutations in all cerebellar regions, with an increased effect compared with that seen in the overall patient group. A potential effect for phenytoin exposure was seen only in the cerebellar vermis, and this did not reach statistical significance after false discovery rate control. The cerebellar volumes, as a fraction of total intracranial volume, are illustrated in Fig 2, and a regression analysis is shown in Fig 3.

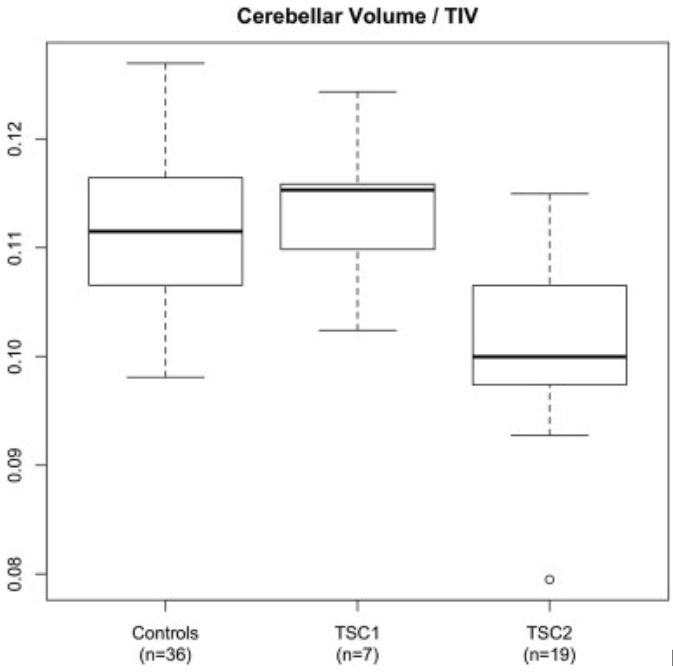

Figure 2

Cerebellar volume is decreased in patients with *TSC2* mutations. Ratio of cerebellar volume to total intracranial volume (TIV) is shown for control subjects, TSC1, and TSC2. Only patients with known pathogenic mutations are included. Boxes show the first to third quartile, with the median indicated by the bold line. The “whiskers” indicate the most extreme data points within 1.5 times the size of the box. Outliers beyond this range are plotted as circles.

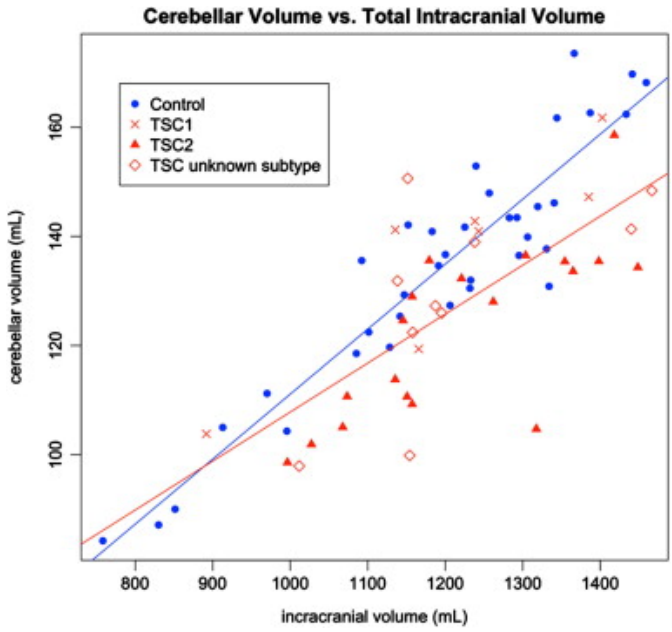

Figure 3

Cerebellar volume is compared with total intracranial volume (TIV) to control for maturational growth. Regression lines are displayed comparing all control subjects (blue line) with all patients (red line). Patients are coded by symbol on the basis of whether a known pathogenic mutation was found and, if so, whether it was *TSC1* or *TSC2*. The patients with *TSC2* mutations (triangles) appear to have smaller cerebella than the patients with *TSC1* mutations (crosses). Patients whose genetic status is unknown appear evenly distributed (diamonds).

Discussion

Most imaging studies in tuberous sclerosis complex to date have focused on the study of lesions associated with the disease. Several authors have investigated the relationship between lesion number, volume, location, and functional outcomes such as epilepsy, autism, and cognitive disorders [9][22][23][24][25][26]. None of these measures is sufficient to explain the range of disease phenotypes observed, with some patients exhibiting widespread tubers but only mild cognitive effects, and other patients with only mild lesion burden, but profound disability. Several groups are investigating alternate indicators of disease, such as white matter microstructure. Our group was the first to report on the relationship between microstructural abnormalities in normal-appearing white matter, as measured with diffusion imaging, and neurodevelopmental outcome [7].

A few studies have examined regional tissue volumes in tuberous sclerosis complex. Ridler et al. [27] undertook a general morphometric study of 10 patients and eight control subjects and demonstrated widespread volumetric differences with the disease, with an *increase* in white matter in affected patients in a region that appears to include the cerebellar peduncles and a gray matter loss in the cerebellar cortex. A larger study of 25 adult patients and control subjects [28] reported a gray matter loss with tuberous sclerosis complex in the cerebellum, as well as deficits in the basal ganglia and brainstem but did not investigate white matter changes. This study reinforces these gray matter observations but finds contradicting evidence with respect to the cerebellar white matter, with our results suggesting a reduction in cerebellar white matter volume in patients with tuberous sclerosis complex.

Cerebellar involvement in tuberous sclerosis complex has been observed in mouse models and in human histologic study. Boer et al. [9] presented immunohistochemical findings from the autopsy of a 32-year-old patient with a *TSC2* mutation. Supratentorial findings in this patient included cortical tubers and subependymal nodules. Examination of the cerebellum revealed no apparent tubers but found cerebellar folia with “prominent” Purkinje cell loss. On the basis of their observation of reactive changes including gliosis and calcifications, they hypothesized that these changes resulted from an ongoing degenerative process, rather than a developmental abnormality.

Recently, Reith et al. [8] generated a mouse mutant where *TSC2* was specifically deleted in cerebellar Purkinje cells. These mutants displayed Purkinje cell apoptosis beginning at 1 month of age, with increasing cell loss demonstrated as mutants aged. The authors subsequently examined four cerebellum samples from patients with tuberous sclerosis complex and age-matched control subjects and reported finding a reduction in Purkinje cell densities in two of the four patients. The authors did not specify whether these patients had *TSC1* or *TSC2* mutations. They did, however, indicate that the samples that exhibited Purkinje cell loss came from patients with a history of seizures and exposure to phenytoin.

In a mouse model, Di Nardo et al. [29] found that absence of the *TSC1/2* gene product complex leads to increased vulnerability to endoplasmic reticular stress and therefore *TSC1/2* serves a neuroprotective role. Reith et al. [8] confirmed this and found that the Purkinje cell loss they observed was due to oxidative and endoplasmic reticular stress. It is unclear whether the loss of this neuroprotective effect alone leads to progressive cellular injury in patients with tuberous sclerosis complex, or whether seizures, medication, or other stressors may contribute as well.

Possibly as many as 90% of patients with tuberous sclerosis complex suffer seizures at one time or another [6], and several therapeutic agents may impact the cerebellum. Phenytoin is known to have potential cerebellar effects when used long term [20]; however, such use has become rare because of its challenging pharmacokinetics, narrow therapeutic window, prominent drug-drug interactions, and long-term side effects. Nonetheless we tested for, and failed to find, an effect caused by the drug. Another potential effect is due to glucocorticoid treatment of infantile spasms. Both acute and long-term exposure during early development may lead to cerebellar volume loss, possibly through apoptosis of the external granule layer [30][31]. Although vigabatrin is the first-line treatment for infantile spasms in tuberous sclerosis complex, three patients were exposed to adrenocorticotropic hormone, and two of these patients were in the *TSC2* group. For this small number of patients, a potential role of the steroids in their cerebellar atrophy cannot be excluded.

Cerebellar tubers have been reported in the literature as common in tuberous sclerosis complex [32][33], but their relationship to genotype and cerebellar volume is not currently known. Images in this study were reviewed for cerebellar tubers by a pediatric neuroradiologist (S.P.P.). Only three patients were affected, one with a *TSC2* mutation and two for whom a known mutation could not be identified. Because of the small numbers encountered in our cohort, we were unable to assess the significance of these lesions.

With respect to the genetics of tuberous sclerosis complex, functional mutations in either *TSC1* or *TSC2* have been associated with the disease, and *TSC1* and *TSC2* are believed to have complementary roles [34]. TSC1 (hamartin) and TSC2 (tuberin) heterodimerize to form a GTPase activating protein complex that inhibits Rheb, itself a key activator of mammalian target of rapamycin, a critical regulator of protein synthesis. Although TSC2 possesses the functional domain, TSC1 is required for stability of TSC2 by preventing its degradation; thus both proteins are required for proper function of the complex, with mutations in either sufficient to result in clinical disease.

Our data may indicate differences in cerebellar volumes on the basis of genotype of tuberous sclerosis complex mutation. Although our *TSC1* mutation–possessing cohort is too small to allow for a firm comparison between genotypes, overall reduced cerebellar volumes appear to be associated with *TSC2* mutation. Despite their complementary nature, the *TSC1* and *TSC2* protein products may serve different roles in nervous system tissue. Gutmann et al. [35] noted a different *subcellular* distribution of TSC1 and TSC2 within the mouse cerebellum, hinting at potential independent functions. Indeed, although both are required for either protein's stability, enzymatic activity lies on TSC2. Thus TSC2 may retain some function in the absence of TSC1, whereas TSC1, lacking a catalytic domain, would be unable to inhibit mammalian target of rapamycin signaling without TSC2 [36]. Furthermore, there are compelling data that patients and mouse models with *TSC2* mutations exhibit more severe neurologic phenotypes [37][38][39][40][41][42][43]. The observed difference between patients with *TSC1* and *TSC2* mutations is therefore plausible and warrants further investigation in a larger cohort.

The cerebellum plays an important role in learning, motor control, and memory [10][11]. Structural abnormalities including congenital lesions and aberrant structure are strongly associated with cognitive impairment [28][33][44], and there is a growing body of literature reporting on the potential role of the cerebellum in autism [44][45][46][47]. In tuberous sclerosis complex specifically, the presence of tubers in the cerebellum has been linked to autism [26][33].

We found that patients with TSC have smaller cerebella than control subjects, with statistically significant reductions in the left and right cerebellar cortex and vermis, as well as no statistically significant reduction in left and right cerebellar white matter. When analyzing a subgroup of 19 patients with *TSC2* mutations, we identified a larger and more widespread pattern of cerebellar volume loss. In this subgroup, we identified statistically significant reductions in left and right cerebellar cortex, in left and right cerebellar white matter, and in the vermis.

Future work should be aimed at uncovering the precise mechanism behind the cerebellar volume loss in tuberous sclerosis complex and its possible relationship to *TSC2* mutations. Histologic and animal model findings suggest a potential degenerative process, but the precise mechanism, and any developmental role, remains unclear. The relationship between this volume change and cognitive outcome in these patients, including autism, will be a topic of future investigation by our group.

[1]. Hyman M.H., Whittemore V.H.: National Institutes of Health consensus conference: tuberous sclerosis complex. Arch Neurol 2000; 57: 662-665

CrossRef

[2]. Curatolo P., Bombardieri R., Jozwiak S.,

et al

: Tuberous sclerosis. Lancet 2008; 372: 657-668

CrossRef

[3]. Winterkorn E.B., Pulsifer M.B., Thiele E.A.,

et al

: Cognitive prognosis of patients with tuberous sclerosis complex. Neurology 2007; 68: 62-64

CrossRef

[4]. Jeste S.S., Sahin M., Bolton P.,

et al

: Characterization of autism in young children with tuberous sclerosis complex. J Child Neurol 2008; 23: 520-525

CrossRef

[5]. Curatolo P., Porfirio M.C., Manzi B.,

et al

: Autism in tuberous sclerosis. Eur J Paediatr Neurol 2004; 8: 327-332

CrossRef

[6]. Yates J.R., Maclean C., Higgins J.N.,

et al

: The Tuberous Sclerosis 2000 Study: presentation, initial assessments and implications for diagnosis and management. Arch Dis Child 2011; 96: 1020-1025

CrossRef

[7]. Peters J.M., Sahin M., Vogel-Farley V.K.,

et al

: Loss of white matter microstructural integrity is associated with adverse neurological outcome in tuberous sclerosis complex. Acad Radiol 2012; 19: 17-25
[8]. Reith R.M., Way S., McKenna J.,

et al

: Loss of the tuberous sclerosis complex protein tuberin causes Purkinje cell degeneration. Neurobiol Dis 2011; 43: 113-122

CrossRef

[9]. Boer K., Troost D., Jansen F.,

et al

: Clinicopathological and immunohistochemical findings in an autopsy case of tuberous sclerosis complex. Neuropathology 2008; 28: 577-590
[10]. O'Halloran C.J., Kinsella G.J., Storey E.,

et al

: The cerebellum and neuropsychological functioning: a critical review. J Clin Exp Neuropsychol 2012; 34: 35-56

CrossRef

[11]. Gordon N.: The cerebellum and cognition. Eur J Paediatr Neurol 2007; 11: 232-234

CrossRef

[12]. Roach E.S., Gomez M.R., Northrup H.,

et al

: Tuberous sclerosis complex consensus conference: revised clinical diagnostic criteria. J Child Neurol 1998; 13: 624-628

CrossRef

[13]. Weisenfeld N.I., Warfield S.K.: Automatic segmentation of newborn brain MRI. Neuroimage 2009; 47: 564-572

CrossRef

[14]. Weisenfeld N.I., Warfield S.K.: Learning likelihoods for labeling (L3): a general multi-classifier segmentation algorithm. Med Image Comput Comput Assist Interv 2011; 14: 322-329

CrossRef

[15]. Avants B.B., Tustison N.J., Song G.,

et al

: A reproducible evaluation of ANTs similarity metric performance in brain image registration. Neuroimage 2011; 54: 2033-2044

CrossRef

[16]. Rohlfing T., Russakoff D.B., Maurer C.R.,

et al

: Performance-based classifier combination in atlas-based image segmentation using expectation-maximization parameter estimation. IEEE Trans Med Imaging 2004; 23: 983-994

CrossRef

[17]. Commowick O., Warfield S.K.: Incorporating priors on expert performance parameters for segmentation validation and label fusion: a maximum a posteriori STAPLE. Med Image Comput Comput Assist Interv 2010; 13: 25-32

CrossRef

[18]. Warfield S.K., Zou K.H., Wells W.M.,

et al

: Simultaneous truth and performance level estimation (STAPLE): an algorithm for the validation of image segmentation. IEEE Trans Med Imaging 2004; 23: 903-921

CrossRef

[19]. Whitwell J.L., Crum W.R., Watt H.C.,

et al

: Normalization of cerebral volumes by use of intracranial volume: implications for longitudinal quantitative MR imaging. AJNR Am J Neuroradiol 2001; 22: 1483-1489

[20]. Crooks R., Mitchell T., Thom M.,

et al

: Patterns of cerebellar atrophy in patients with chronic epilepsy: a quantitative neuropathological study. Epilepsy Res 2000; 41: 63-73

CrossRef

[21]. Benjamini Y., Hochberg Y.: Controlling the false discovery rate: a practical and powerful approach to multiple testing. J Roy Statist Soc Ser B 1995; 57: 289-300

[22]. DiMario F.J.: Brain abnormalities in tuberous sclerosis complex. J Child Neurol 2004; 19: 650-657

[23]. Ridler K., Suckling J., Higgins N.,

et al

: Standardized whole brain mapping of tubers and subependymal nodules in tuberous sclerosis complex. J Child Neurol 2004; 19: 658-665

[24]. Numis A.L., Major P., Montenegro M.A.,

et al

: Identification of risk factors for autism spectrum disorders in tuberous sclerosis complex. Neurology 2011; 76: 981-987

CrossRef

[25]. Bolton P.F., Park R.J., Higgins J.N.,

et al

: Neuro-epileptic determinants of autism spectrum disorders in tuberous sclerosis complex. Brain 2002; 125: 1247-1255

CrossRef

[26]. Weber A.M., Egelhoff J.C., McKellop J.M.,

et al

: Autism and the cerebellum: evidence from tuberous sclerosis. J Autism Dev Disord 2000; 30: 511-517

CrossRef

[27]. Ridler K., Bullmore E.T., De Vries P.J.,

et al

: Widespread anatomical abnormalities of grey and white matter structure in tuberous sclerosis. Psychol Med 2001; 31: 1437-1446

[28]. Ridler K., Suckling J., Higgins N.J.,

et al

: Neuroanatomical correlates of memory deficits in tuberous sclerosis complex. Cereb Cortex 2007; 17: 261-271

CrossRef

[29]. Di Nardo A., Kramvis I., Cho N.,

et al

: Tuberous sclerosis complex activity is required to control neuronal stress responses in an mTOR-dependent manner. J Neurosci 2009; 29: 5926-5937

CrossRef

[30]. Noguchi K.K., Walls K.C., Wozniak D.F.,

et al

: Acute neonatal glucocorticoid exposure produces selective and rapid cerebellar neural progenitor cell apoptotic death. Cell Death Differ 2008; 15: 1582-1592

CrossRef

[31]. Noguchi K.K., Lau K., Smith D.J.,

et al

: Glucocorticoid receptor stimulation and the regulation of neonatal cerebellar neural progenitor cell apoptosis. Neurobiol Dis 2011; 43: 356-363

CrossRef

[32]. Ertan G., Arulrajah S., Tekes A.,

et al

: Cerebellar abnormality in children and young adults with tuberous sclerosis complex: MR and diffusion weighted imaging findings. J Neuroradiol 2010; 37: 231-238

CrossRef

[33]. Eluvathingal T.J., Behen M.E., Chugani H.T.,

et al

: Cerebellar lesions in tuberous sclerosis complex: neurobehavioral and neuroimaging correlates. J Child Neurol 2006; 21: 846-851

CrossRef

[34]. Tsai P., Sahin M.: Mechanisms of neurocognitive dysfunction and therapeutic considerations in tuberous sclerosis complex. Curr Opin Neurol 2011; 24: 106-113

CrossRef

[35]. Gutmann D.H., Zhang Y., Hasbani M.J.,

et al

: Expression of the tuberous sclerosis complex gene products, hamartin and tuberin, in central nervous system tissues. Acta Neuropathol 2000; 99: 223-230

CrossRef

[36]. Benvenuto G., Li S., Brown S.J.,

et al

: The tuberous sclerosis-1 (TSC1) gene product hamartin suppresses cell growth and augments the expression of the TSC2 product tuberin by inhibiting its ubiquitination. Oncogene 2000; 19: 6306-6316

CrossRef

[37]. Dabora S.L., Jozwiak S., Franz D.N.,

et al

: Mutational analysis in a cohort of 224 tuberous sclerosis patients indicates increased severity of TSC2, compared with TSC1, disease in multiple organs. Am J Hum Genet 2001; 68: 64-80

CrossRef

[38]. Zeng L.H., Rensing N.R., Zhang B.,

et al

: Tsc2 gene inactivation causes a more severe epilepsy phenotype than Tsc1 inactivation in a mouse model of tuberous sclerosis complex. Hum Mol Genet 2011; 20: 445-454

CrossRef

[39]. Langkau N., Martin N., Brandt R.,

et al

: TSC1 and TSC2 mutations in tuberous sclerosis, the associated phenotypes and a model to explain observed TSC1/TSC2 frequency ratios. Eur J Pediatr 2002; 161: 393-402

CrossRef

[40]. Lewis J.C., Thomas H.V., Murphy K.C.,

et al

: Genotype and psychological phenotype in tuberous sclerosis. J Med Genet 2004; 41: 203-207

CrossRef

[41]. Au K.S., Williams A.T., Roach E.S.,

et al

: Genotype/phenotype correlation in 325 individuals referred for a diagnosis of tuberous sclerosis complex in the United States. Genet Med 2007; 9: 88-100

CrossRef

[42]. Sancak O., Nellist M., Goedbloed M.,

et al

: Mutational analysis of the TSC1 and TSC2 genes in a diagnostic setting: genotype–phenotype correlations and comparison of diagnostic DNA techniques in tuberous sclerosis complex. Eur J Hum Genet 2005; 13: 731-741

CrossRef

[43]. Jones A.C., Shyamsundar M.M., Thomas M.W.,

et al

: Comprehensive mutation analysis of TSC1 and TSC2-and phenotypic correlations in 150 families with tuberous sclerosis. Am J Hum Genet 1999; 64: 1305-1315

CrossRef

[44]. Bolduc M.E., du Plessis A.J., Sullivan N.,

et al

: Regional cerebellar volumes predict functional outcome in children with cerebellar malformations. Cerebellum 2012; 11: 531-542

CrossRef

[45]. Courchesne E., Saitoh O., Townsend J.P.,

et al

: Cerebellar hypoplasia and hyperplasia in infantile autism. Lancet 1994; 343: 63-64

CrossRef

[46]. Hodge S.M., Makris N., Kennedy D.N.,

et al

: Cerebellum, language, and cognition in autism and specific language impairment. J Autism Dev Disord 2010; 40: 300-316

CrossRef

[47]. Tsai P.T., Hull C., Chu Y.,

et al

: Autistic-like behaviour and cerebellar dysfunction in Purkinje cell Tsc1 mutant mice. Nature 2012; 488: 647-651

CrossRef