

Super-resolution multi-fascicle imaging reveals the presence of both radial and tangential diffusion in the mature cortex using a clinical scanner.

Benoit Scherrer¹, Ali Gholipour¹, Mustafa Sahin², Sanjay P Prabhu¹, and Simon K. Warfield¹

¹Radiology, Harvard Medical School, Boston Children's Hospital, Boston, MA, United States, ²Neurology, Harvard Medical School, Boston Children's Hospital, Boston, MA, United States

PURPOSE – While radial diffusion has been reported at early stages in cortical development¹, the dominance of radial diffusion² or tangential diffusion³ in the mature cortex is still matter of debate. Recently, McNab *et al.*⁴ have reported using in vivo human subjects, fixed human brain specimen and anesthetized macaques that while mostly radial diffusion persists, tangential diffusion may exist in particular cortex regions. All the previous studies were performed using the single tensor model at each voxel. In this work, we demonstrate that when employing a multi-fascicle model at each voxel and high resolution super-resolution diffusion imaging, the presence of both radial and tangential diffusion can be observed in each grey matter voxel with a clinical scanner.

METHODS – We achieved isotropic high resolution (HR) k-space sampling by imaging of a series of three orthogonal anisotropic $1.25 \times 1.25 \times 2 \text{mm}^3$ acquisitions (axial, coronal, and sagittal) and by recovering the underlying HR images via super-resolution reconstruction⁵. The acquisitions were performed on a Siemens 3T Trio with a 32 channel head coil and the following parameters: FOV = 240 mm, matrix = 192×192 , in-plane resolution = $1.25 \times 1.25 \text{mm}^2$, slice-thickness = 2mm, the number of slices varying from 70 to 90 depending on the acquisition orientation. We employed the Cube and Sphere (CUSP) gradient encoding scheme⁶, which enables imaging of a large number of non-zero b-values (necessary to estimate the parameters of a multi-fascicle model⁶) with short TE, high SNR and high angular coverage by appropriate application of the gradient system. Each acquisition was composed of 5 $b = 0 \text{ s/mm}^2$ and 60 directions between $b = [1000-3000] \text{ s/mm}^2$ (CUSP65)⁶. The total acquisition duration time for the three scans was approximately 45 minutes. We also acquired for each orientation a pair of $b = 0$ images with opposite phase encoding directions. The susceptibility-induced off-resonance field was estimated from the pairs of $b = 0$ images and the geometric and intensity distortion of each orthogonal scan corrected for. Finally, a $1 \times 1 \times 1 \text{mm}^3$ T1-weighted MPRAGE image was acquired for visualization purpose (176 slices, FOV = 220mm, matrix = 220×220 , TE = 3.39ms, TR = 2530ms). The super-resolution reconstruction of each DW image was achieved at $1 \times 1 \times 1 \text{mm}^3$. As described by $r_{\text{iso}}^{\text{max}} = (r_{\text{LR}} r_{\text{HR}}^2 / 3)^{1/3}$ (r_{HR} : HR in-plane voxel dimension; r_{LR} : low-resolution slice thickness), this corresponds to a reconstruction for which the number of HR voxels to estimate matches the number of LR observations⁵. A multi-fascicle model was estimated at each voxel⁶. Each fascicle was represented by a tensor and free water diffusion was modeled with an additional isotropic tensor with fixed diffusivity ($D_{\text{iso}} = 3 \cdot 10^{-3} \text{ mm}^2/\text{s}$). The number of fascicles was estimated at each voxel by minimizing the generalization error.

RESULTS – We report in Fig.1 the estimated fascicle directions superimposed on the T1-weighted image. The grey matter boundaries were manually delineated from the T1-weighted image (yellow). Fig b-e show various zooms of a same slice (Fig.a). They show that super-resolution multi-fascicle imaging enables delineation of the WM projections to the cortex and demonstrate the presence of both radial and tangential diffusion in each GM voxel in the mature cortex.

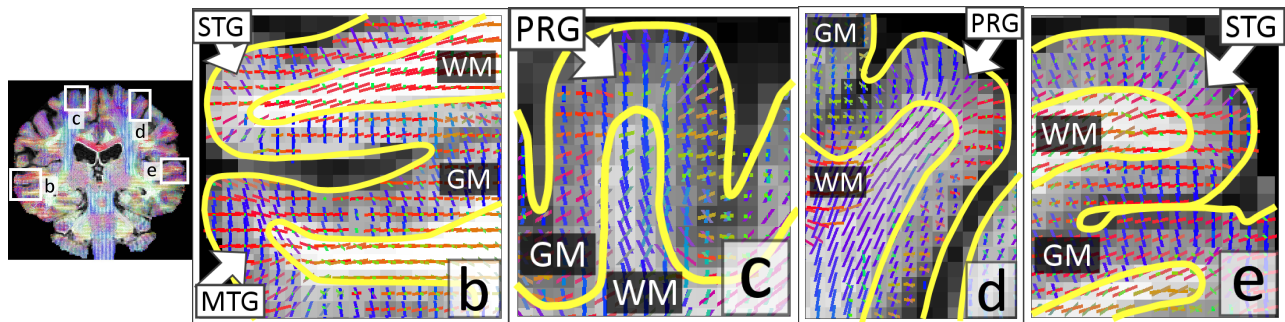


Fig1. Super-resolution multi-fascicle imaging reveals the presence of both radial and tangential diffusion in the cortex GM using 3 Tesla clinical scanner with moderate gradient strength (40mT/m) (STG/MTG: Superior/Middle Temporal Gyrus; PRG: Precentral Gyrus)

CONCLUSION – High-resolution high-SNR DW imaging is crucial to investigating the structure of the diffusion in the grey matter. We overcame the challenges of increasing the spatial resolution by imaging a series of scans with high resolution along only a limited number of dimensions. This reduces the scanner burden for each scan and achieves higher SNR. The high resolution images were then reconstructed in the image domain using an image generation model⁵. In contrast to tract density imaging⁶, this does sample higher frequencies in k-space and can be referred to as *quantitative super-resolution imaging*. We employed a gradient encoding scheme that images multiple non-zero b-values so that the parameters of a multi-fascicle model can be estimated. We demonstrated that the obtained multi-fascicle models at each voxel reveal the presence of both radial and tangential diffusion in the cortex GM. It is likely that the observation of either radial or tangential diffusion in^{1,2,3,4} was due to using an oversimplified model, the single tensor model. In future work, we will evaluate the use of multi-band imaging to investigate the structure of the cortex GM in clinically compatible scan time.

REFERENCES – 1. McKinstry, R.C. et al, Radial Organization of Developing Preterm Human Cerebral Cortex Revealed by Non-invasive Water Diffusion Anisotropy MRI, *Cereb. Cortex*, 12, 1237-43; 2. Miller K.L. et al., Diffusion imaging of whole, post-mortem human brains on a clinical MRI scanner, *Neuroimage*, 2011, 57, 167-181; 3. Golay, X et al, High-resolution isotropic 3D diffusion tensor imaging of the human brain, 2002, *Magn. Reson. Med.* 47, 837-843; 4. McNab J.A. et al, Surface based analysis of diffusion orientation for identifying architectonic domains in the in vivo human cortex, *Neuroimage*, 2013, 69, 87-100. 5. Scherrer, B., A. Gholipour, and S.K. Warfield, Super-resolution reconstruction to increase the spatial resolution of diffusion weighted images from orthogonal anisotropic acquisitions. *Med Image Anal.* 2012, 16(7), 1465-1476 ; 6. Scherrer, B. and S.K. Warfield, Parametric representation of multiple white matter fascicles from cube and sphere diffusion MRI. *PLoS One*, 2012, 7(11); 7. Calamante F. et al, Track-density imaging (TDI): super-resolution white matter imaging using whole-brain track-density mapping, *Neuroimage*, 2010, 53(4), 1233-1243. 1. Scherrer, B., M. Taquet, and S.K. Warfield, Reliable Selection of the Number of Fascicles in Diffusion Images by Estimation of the Generalization Error. *Inf Process Med Imaging*, 2013, 23(7917): p. 742-753.